

Actinomyces

Gram-positive irregularly staining bacteria. Produce branching filaments, although diphtheroid cells and branched rods are also commonly seen.

Non acid-fast, non-spore-forming, non motile and fermentative.

Microaerophilic or anaerobic and catalase negative (except *A. viscosus*).

All pathogens of animals are commensals of the oral cavity.

Actinomyces bovis

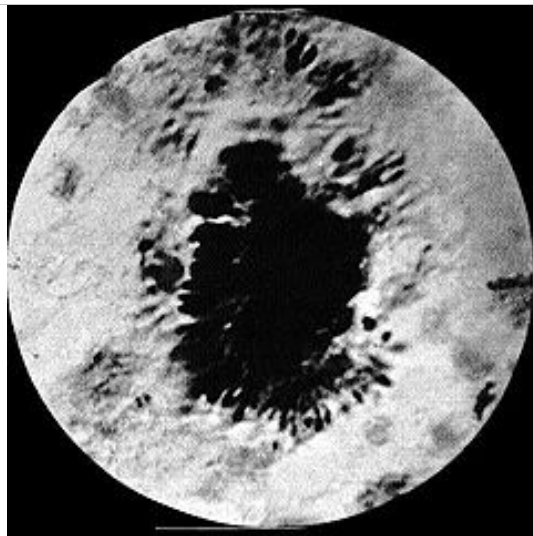
Specimen Collection

Pus from lesion.

Microscopic Examination of Tissues

Wet Mounts

Wet mount of crushed granule in pus from a case of bovine lumpy jaw. Club-shaped structures can be seen at the periphery.



Pus should be washed in distilled water in a petri dish to expose small 1 to 3 mm sulphur granules (cf <1 mm grey-white granules in actinobacillosis).

Gently crush the granules under a cover slip and examined as a wet mount under low power to reveal club-shaped structures.

Gram Smear

The coverslip is removed and the crushed granule stained by the Gram method. The organisms appear as delicate Gram-positive branching filaments surrounded by radiating Gram-negative "clubs".

This structures are referred to as a club colonies.

Club colonies are also found in actinobacillosis, botryomycosis, and rarely in *A. pyogenes* infections.

Cultural Examination

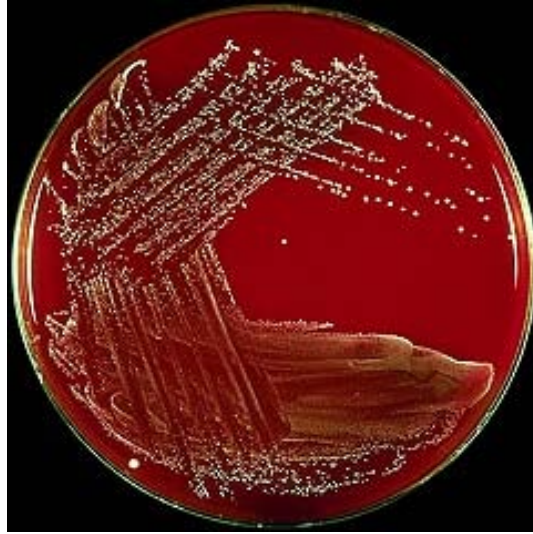Anaerobe which grows best in presence of CO₂

Pus from actinomycotic lesions should ideally be inoculated onto pre-reduced freshly prepared SBA or brain heart infusion agar and into freshly boiled (and cooled) thioglycollate broth enriched with serum or yeast extract.

Plates and broths should be incubated in an anaerobic jar with 5 to 10 % CO₂ for 3 to 5 d at 35° C to 37° C.

A plain Sabouraud dextrose agar plate should also be inoculated and incubated at 37° C and room temperature. *Actinomyces* sp. grow very poorly, if at all on Sabouraud agar, whereas *Nocardia* grows well.

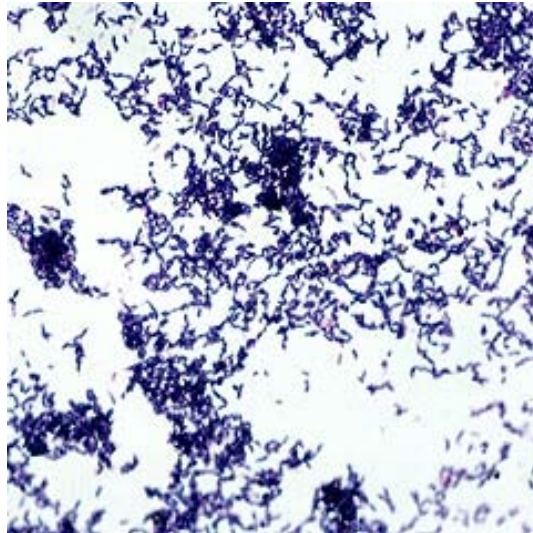
Actinomyces bovis on sheep blood agar after 4 days in anaerobic conditions with 10 % CO₂.



Colonies 0.5 to 1 mm diameter, convex, opaque and butyrous with a smooth or granular surface. They are difficult to remove from the agar.

No growth or very sparse growth occurs aerobically.

Gram stained smear of a culture of *Actinomyces bovis*



There are masses of Gram-positive rods and slightly branched filaments in smears prepared from cultures.

Identification

Characteristic lesions, presence of sulphur granules and demonstration of Gram-positive branching filaments is usually sufficient to make a diagnosis.

Catalase: Negative

Nitrate: Not reduced

Starch: Hydrolysed

Aesculin: Hydrolysed

Serology

Not used diagnostically.

Antibiotic Susceptibility

Sensitive to penicillins, cephalosporin, sulphonamides, tetracyclines, and lincomycin. Prolonged

treatment is required.

Actinomyces viscosus

Specimen Collection

Pus from superficial abscess.

Pleural fluid collected by thoracentesis.

Microscopic Examination of Tissues

Pus contains soft grey actinomycotic granules containing Gram-positive, nonacid-fast filamentous organisms (resemble *A. bovis*).

Examine as for *A. bovis*.

Cultural Examination

More oxygen tolerant than *A. bovis* and grows equally well aerobically and anaerobically.

Grows well on SBA. Does not grow on Sabouraud dextrose agar.

Colonies apparent in 3 to 7 days. They are convex to heaped, smooth, cream to white in colour, soft or mucoid. Aerial hyphae reported.

Identification

Catalase positive.